



**PATIENT**

Gibson Perry

**SPECIES**

Canine

**BREED**

French Bulldog

**SEX**

Male Neutered

**AGE**

4 years

**WEIGHT**

24.4lbs

**INTERPRETED BY**

Maggie Machen Lamy, DVM DACVIM (Cardiology)

**IMAGING PERFORMED BY**

Pamela Harrigan, RDCS

**HOSPITAL NAME**

Mass Veterinary Services

**REFERRING VET**

Dr. Masloski

**INVOICE**

25783

**DATE**

8/16/22

**PRESENTING CLINICAL SIGNS**

History: Gibson was seen for vomiting in April. Radiographs revealed borderline cardiomegaly. He has breathing/regurgitation issues with regurgitation noted after he eats. He is eating and drinking well but does have some exercise intolerance. Upper airway stridor as well as stenotic nares. Planning BOAS procedure. On exam: NSR, no murmurs noted, PSS, lung fields clear with referred upper airway noise, stridor noted, stenotic nares noted. BP: 120mmHg x 4 \*No sedation for study.

**ECHOCARDIOGRAM FINDINGS**

2D, m-mode, color flow and Doppler imaging is available.

**Left ventricle:** The LV diameter is normal with adequate myocardial function. LV wall thicknesses are normal.

**Left atrium:** The left atrium is normal.

**Mitral valve:** The mitral valve is mildly thickened with no prolapse into the left atrial lumen. No MR.

**Aortic valve/Aorta:** The aortic valve is normal in morphology and mobility. Normal aortic outflow velocity depending on heart rate; laminar flow. No aortic insufficiency.

**Right ventricle:** Normal right ventricular diameter and morphology indicating no overt evidence of pulmonary arterial hypertension.

**Right atrium:** Normal RA dimension.

**Tricuspid valve:** The tricuspid valve appears normal with no tricuspid regurgitation.

**Pulmonic valve/Pulmonary artery:** The pulmonic valve is normal in morphology and mobility. No pulmonic insufficiency. Normal RVOT velocity; laminar flow.

**Pericardium/other:** No pericardial or pleural effusion noted. No obvious cardiac masses.

**Heart rhythm:** ECG reveals a sinus rhythm with an average HR of 150bpm.

**2-Dimensional Measurements**

Ao diam (cm)	1.7
LA diam (cm)	2.0
LA:Ao (Swe)	1.2
IVS thickness (cm)	0.76
LVID diastole (cm)	3.0
PW thickness (cm)	0.73
LVID systole (cm)	1.1
FS (%)	63

**Doppler Measurements**

PV Vmax (m/s)	0.9
AoV Vmax (m/s)	1.2
MR Vmax (m/s)	NA
TR Vmax (m/s)	NA
TR PG (mmHg)	NA

**INTERPRETATION OF THE FINDINGS**

Overtly normal cardiac structure and function. The overall dimensions are normal with no evidence of significant structural disease. Follow up is advised should a murmur be ausculted in the future. No additional issues are identified.

These findings would suggest the radiographic abnormality is a normal variant. These films should be used as a baseline for future comparison.

**RECOMMENDATIONS**

- No cardiac medications are clearly indicated.
- No cardiac contraindication for general anesthesia.
- Monitor for development of a cough, labored breathing, exercise intolerance or collapse episodes.



**PATIENT**

Gibson Perry

**PLAN**

- Recommend conservative monitoring with a recheck echocardiogram should a murmur or signs of cardiac compromise be noted in the future.

**SPECIES**

Canine

**BREED**

French Bulldog

**SEX**

Male Neutered

**AGE**

4 years

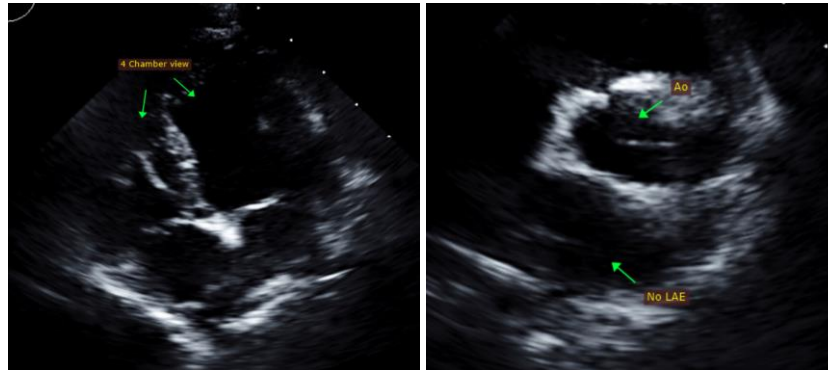
**WEIGHT**

24.4lbs

**INTERPRETED BY**

Maggie Machen  
Lamy, DVM  
DACVIM (Cardiology)

**IMAGES**



The information and recommendations provided are based on the images presented by the referring veterinarian. No evaluation can be communicated regarding pathology that was not visible in the image/video clips provided.

Thank you for this referral. This report was generated using transcription software, and minor dictation errors may be present. If the clinical or image interpretation does not parallel your findings or if I can be of any further assistance, please contact me.

Maggie Machen Lamy, DVM  
Diplomate of the American College of Veterinary Internal Medicine (Cardiology)  
info@sonopath.com

**Echocardiogram performed by:**

Pamela Harrigan, RDCS  
Pet Animal Ultrasound Service (4paus.com)

**IMAGING PERFORMED BY**

Pamela Harrigan,  
RDCS

**HOSPITAL NAME**

Mass Veterinary  
Services

**REFERRING VET**

Dr. Masloski

**INVOICE**

25783

**DATE**

8/16/22